34

BURTON P. DRAYER, MD, CONSULTING EDITOR

NEUROIMAGING CLINICS OF NORTH AMERICA

The Lumbosacral Spine

J. RANDY JINKINS, MD, GUEST EDITOR

VOLUME 3 • NUMBER 3 • AUGUST 1993

W. B. SAUNDERS COMPANY
A Division of Harcourt Brace & Company
PHILADELPHIA LONDON TORONTO MONTREAL SYDNEY TOKYO

1052-5149/93 $0.00 + .20

THE PATHOANATOMIC BASIS OF SOMATIC AND AUTONOMIC SYNDROMES ORIGINATING IN THE LUMBOSACRAL SPINE

J. Randy Jinkins, MD

The clinical state of neurogenic spinal radiculopathy accompanying nerve root, spinal nerve, and dorsal root ganglion injury may be associated with a definite vertebrogenic clinical syndrome. The combined symptom complex includes (1) local and referred pain, (2) radicular pain and paresthesias, (3) muscular dysfunction, (4) autonomic reflex dysfunction within the lumbosacral zones of Head, and (5) generalized alterations in viscerosomatic tone. These dual syndromes, somatic and autonomic, may be superimposed. The anatomic basis for the origin and mediation of clinical signs and symptoms related to the lumbosacral neural plexus rests with (1) afferent and efferent somatic neural branches emanating from the ventral and dorsal rami of the spinal nerve, (2) neural rami projecting directly to and originating from the paravertebral autonomic neural plexus, and (3) the dorsal and ventral spinal nerve roots and spinal nerves themselves. These fibers originate and terminate in the spinal column and related nontissues, in neural tissue, and in distant peripheral tissues. Thus conscious perception and unconscious effects originating from the vertebral column and its neural structures, although complex, have definite pathways represented in this network of innervation associated with intimately related or parallel peripheral and central nervous system (CNS) ramifications.

ANATOMY OF SOMATIC SPINAL SYNDROMES

Somatic Innervation of Ventral Spinal Elements

The anatomic basis for discogenic and therefore vertebrogenic pain generated by all disc extrusions rests partially with somatic fibers originating from the recurrent meningeal nerve (sinuvertebral nerve of Luschka) supplying the posterior longitudinal ligament, the meninges, the blood vessels, the posterior extent of the outermost fibers of the annulus fibrosus, a portion of the periosteum of the vertebral bodies, and the underlying bone. In addition, a variable small branch from the ventral ramus of the somatic spinal nerve root may directly innervate the posterolateral aspect of the vertebral body and related issues over an inconstant range. Any traumatic involvement of these neural and non-

From the Section of Neuroradiology, Department of Radiology, The University of Texas Health Science Center at San Antonio, San Antonio, Texas

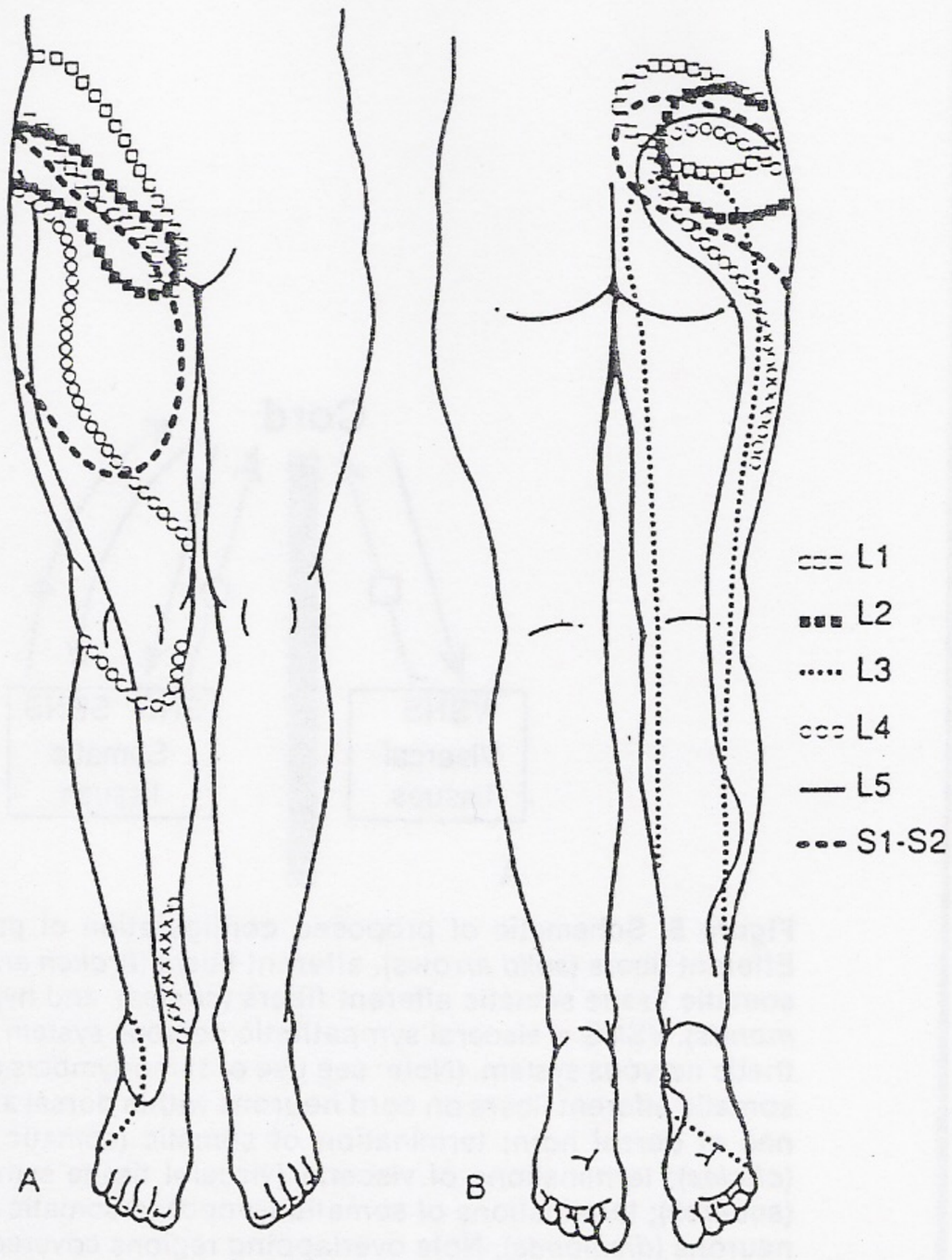

Figure 4. Right unilateral composite of lumbosacral Head zones of pain referral and proposed reflex autonomic dysfunction referral from segmental spinal levels. *A*, Anterior and *B*, posterior aspects. Note constricted, superimposed, and skipped regions. (*Adapted from* Jinkins JR, Whittemore AR, Bradley WG: The anatomic basis of vertebrogenic pain and the autonomic syndrome associated with lumbar disk extrusion. AJNR Am J Neuroradiol 10:219–231, 1989, *and* AJR Am J Roentgenol 152:1277–1289, 1989, © by American Society of Neuroradiology; with permission.)

nomic fibers as they are with afferent and efferent ramifications of native somatic nerves. Therefore the autonomic projection fields may be somewhat functionally contracted. The restricting, superimposing effects of the ascending lumbar sympathetic afferent diversion detailed earlier may also be a major factor. These general anatomic concepts help to clarify some of the mechanisms within the peripheral nervous system responsible for the rather nebulous fields characteristic of the zones of Head.

As the foregoing seems to indicate, the entire network resulting in the perception of referred pain could be mediated within the autonomic (sympathetic) somatotopic organization of the CNS running in parallel with somatic afferent systems. The peripheral neurologic system follows two patterns during embryologic development. The somatic nervous system has one distribution, which ramifies solely within the somatic tissues. The autonomic nervous system, however, develops along two different pathways: (1) within visceral structures sometimes referred to as the visceral autonomic nervous system and (2) within the somatic tissues in a distribution similar to that of the peripheral somatic nerves, although possibly not along such discretely demarcated lines. Identical to the functional sympathetic efferent connections within somatic tissues, there must also be parallel sympathetic afferent links to the CNS to complete somatic tissue autonomic reflex arcs. Therefore, functionally at least, the existence of *somatic* afferent sympathetic fibers is proved (Fig. 5). In fact, the presence of these peripheral autonomic afferent fibers

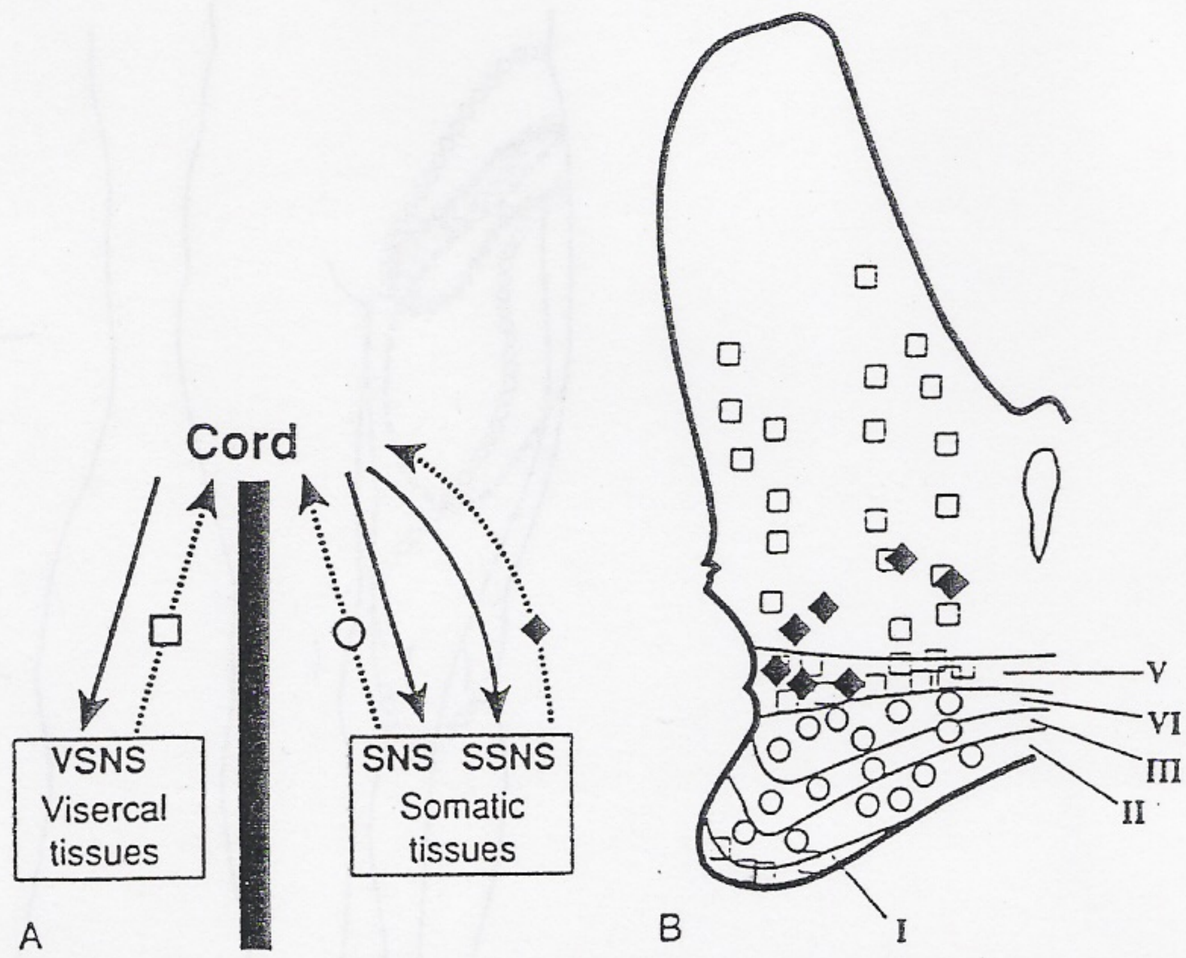

Figure 5. Schematic of proposed configuration of peripheral nervous system and its central terminations. *A*, Efferent fibers (*solid arrows*), afferent fibers (*broken arrows*), visceral tissue sympathetic afferent fibers (*squares*), somatic tissue somatic afferent fibers (*circles*), and hypothesized somatic tissue sympathetic afferent fibers (*diamonds*). VSNS = visceral sympathetic nervous system; SNS = somatic nervous system; SSNS = somatic sympathetic nervous system. (Note: see use of same symbols and meanings in *B*.) *B*, Points of termination of visceral and somatic afferent fibers on cord neurons within dorsal and ventral gray matter of right spinal hemicord; I–V = laminae of dorsal horn; termination of somatic (somatic tissue somatic) afferent fibers on somatic cord neurons (*circles*); terminations of visceral (visceral tissue sympathetic) afferent fibers on viscerosomatic cord neurons (*squares*); terminations of somatic (proposed somatic tissue sympathetic) afferent fibers on viscerosomatic cord neurons (*diamonds*). Note overlapping regions covered by squares and diamonds that result in a central nervous system convergence of afferent fibers from divergent origins. (*Adapted from* Jinkins JR, Whittemore AR, Bradley WG: The anatomic basis of vertebrogenic pain and the autonomic syndrome associated with lumbar disk extrusion. AJNR Am J Neuroradiol 10:219–231, 1989, *and* AJR Am J Roentgenol 152:1277–1289, 1989, © by American Society of Neuroradiology; with permission.)

within somatic tissues has been demonstrated clinically.[49] Because both visceral and somatic tissues are innervated by the sympathetic nervous system and assuming that both tissues are served by afferent limbs, the CNS may then perceive an impulse origin within either tissue on the basis of a central embryologically predetermined linkage. In actuality, however, the CNS may not be able to discriminate accurately spatially between the visceral and the somatic origin of a stimulus in certain circumstances. Thus a visceral sympathetic afferent stimulus may erroneously be consciously perceived as arising within the somatic sector of the sympathetic afferent sensory projection field and by definition is thus referred to this location. The converse of this phenomenon might also be true, although perhaps more rarely perceived.

This explanation concisely fits the observation of referral of visceral sympathetic stimuli (e.g., cardiac pain) to the somatic sympathetic afferent projection field (e.g., left shoulder) and vice versa, thereby defining the zones of Head predominantly or entirely as a phenomenon of a developmentally dichotomous sympathetic nervous system ramifying within the visceral and the somatic tissues. In this functional context, referred actions and perceptions are an expected capacity of the autonomic (sympathetic) nervous system, rather than a truly abnormal phenomenon. Thus the ascending afferent lumbar sympathetic diversion accounts for extrasegmental CNS misregistration and patterns of mismapped superimposition of pain within the lumbosacral zones of Head, but the actual primary referral seems to result from mediation of the painful stimulus within the autonomic nervous system itself.[49]

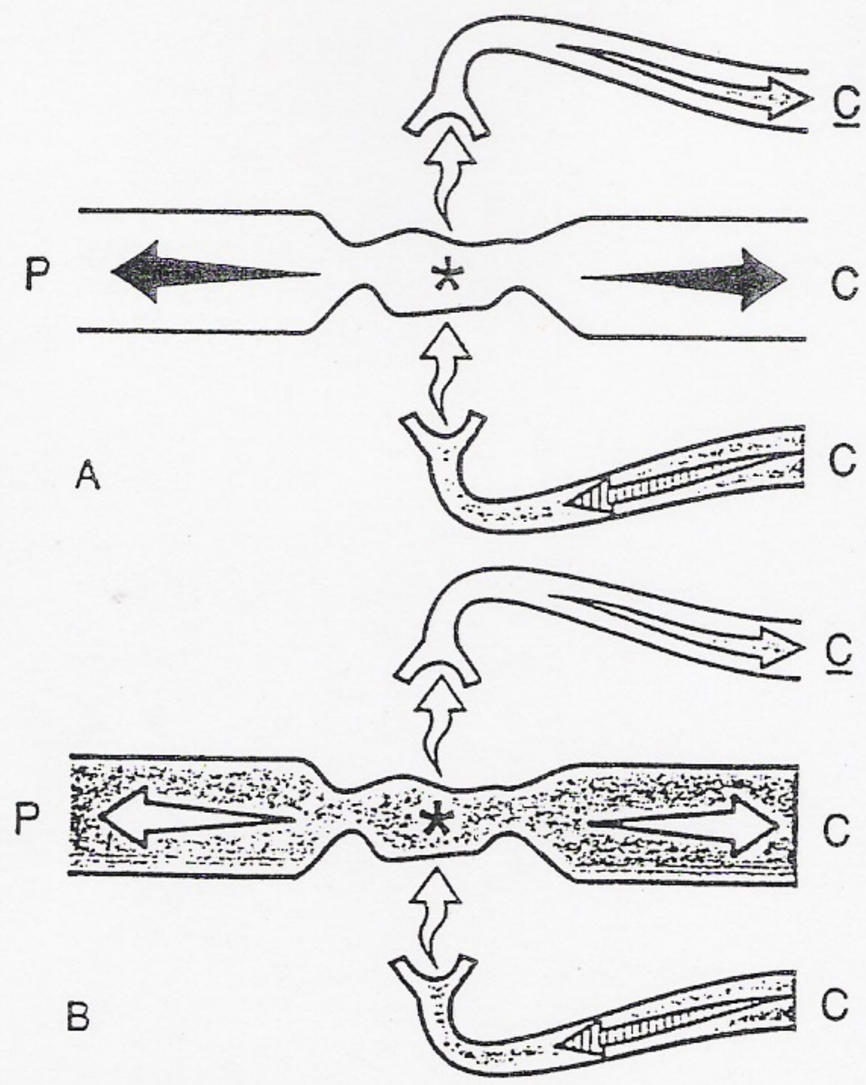

Figure 16. Aberrant neuroelectrical activity driven by outgoing autonomic efferent impulse resulting in ephaptic stimulation and transmission respectively between autonomic efferent *nervi nervorum* (*shaded bifid channels*), an injured adjacent axon (*wavy contoured channels*), and the afferent somatic or autonomic *nervi nervorum* (*open bifid channels*). These phenomena could occur hypothetically in spinal dorsal roots (*A*), ventral roots (*B*), or in combined spinal nerves (*A* and *B*).

A, Incoming neuroelectrical impulse (*hatched arrow*) within efferent autonomic axon (*shaded bifid channel*) of the *nervi nervorum* results in ephaptic stimulation (*lower open serpentine arrow*) axo-axonally and depolarization (*asterisk*) at site of injured afferent axon (*wavy contour, open channel:* somatic or autonomic) acting as ectopic receptor and effecting central (C) and peripheral (P) aberrant afferent axon impulse propagation (*solid straight arrows*). At the same time, ephaptic transmission (*upper open serpentine arrow*) axo-axonally causes stimulation of normal or injured (sensitized) receptor (*open bifid channel:* somatic or autonomic) of afferent *nervi nervorum* and effects central (C) aberrant afferent axon impulse propagation (*stippled arrow*).

B, Incoming neuroelectrical impulse (*hatched arrow*) within normal or injured efferent autonomic axon (*shaded bifid channel*) of the *nervi nervorum* results in ephaptic stimulation (*lower open serpentine arrow*) axo-axonally and depolarization (*asterisk*) at site of injured efferent axon (*wavy contour, shaded channel:* somatic or autonomic) acting as ectopic receptor and effecting central (C) and peripheral (P) aberrant efferent axon impulse propagation (*open straight arrows*). At the same time, ephaptic transmission (*upper open serpentine arrow*) axo-axonally causes stimulation of normal or injured (sensitized) receptor (*open bifid channel:* somatic or autonomic) of afferent *nervi nervorum* and effects central (C) aberrant afferent axon impulse propagation (*stippled arrow*).

SUMMARY

In common practice, a far-reaching, perplexing, combined vertebroneurogenic, somatoautonomic syndrome stems from spinal disease that includes varying degrees of (1) local somatic pain, (2) centrifugal referred pain, (3) centrifugal radiating pain, (4) referred sympathetic reflex dysfunction (diaphoresis, piloerection, vasomotor changes, somatic muscle spasm), (5) somatic reflex dysfunction, (6) somatic muscle weakness, (7) centrifugal somatic dysesthesias, and (8) generalized alterations in viscerosomatic tone (blood pressure, heart rate, respiratory rate, alertness). The somatic syndrome (including numbers 1, 3, and 5 through 7 above) is mediated within the main somatic spinal nerve roots, or direct somatic branches thereof, in conjunction with the CNS. It is proposed that the autonomic syndrome (including numbers 2, 4, 7, and 8 above) is predominantly if not entirely mediated within the peripheral and central ramifications of the sympathetic nervous system.

Anatomically there is a single afferent and efferent network of the somatic nervous system that arborizes within the somatic tissues. The sympathetic nervous system, however, also has efferent connections within both visceral and somatic tissues. In addition, there are afferent sympathetic fibers within the visceral tissues, and research data support the hypothesis that somatic tissue sympathetic afferents exist as well. Experimental evidence indicates that most of the somatic and sympathetic nervous system afferents terminate within separate regions of the gray matter of the spinal cord. Nevertheless, incoming sympathetic impulses from distantly separated visceral and somatic sources may drive the *same* viscerosomatic cord neurons by two methods. First, two different sympathetic afferent fibers, one of visceral origin and the other of somatic origin, may terminate on the same cord neuron or associated cord interneurons. Second, bifurcating afferent fibers, with one limb each ramifying within the somatic and the visceral tissues, may terminate a single shared central axon within the spinal cord gray matter. Either or both of these anatomic configurations may be operative.

In addition, aberrant neuroelectrical phenomena may result from ephaptic transmission within or between the som-